

III Degenerative Disc Disease

13 Clinical Presentation of Disc Degeneration

Andrew P. White, Eric L. Grossman, and Alan S. Hilibrand

The intervertebral disc (IVD) is a vital and dynamic component of spinal architecture (**Fig. 13.1**). It assists in the distribution of loads and allows for stable yet complex motion. Over time, the disc undergoes a characteristic aging process that is manifested by consistent radiographic changes. In some patients, certain clinical signs and symptoms associated with disc degeneration may also be present.

With advanced degeneration, the disc becomes less competent in appropriately distributing loads, and an alteration of normal spinal biomechanics may result. Increased strain on related structures, including the paired facet joints, can occur and can be associated with varied pathology. Regardless of the underlying physiologic process, the most common symptom seen with degenerative disc disease (DDD) is low back pain (LBP), which in a minority of patients may also be accompanied by neurologic symptoms.¹

■ Pathophysiology of Disc Degeneration

Repetitive mechanical loading may be related to the characteristic physiologic aging of the spine. Other factors may also be related, including the diminished porosity of the lamina cribrosa, resulting in decreased diffusion of nutrients and waste products. Over time, the IVD undergoes a characteristic degenerative process, with associated signs and symptoms often incident in the third decade. Early degeneration, including disc desiccation and loss of viscoelastic properties, leads to an alteration of spinal biomechanics. This can accelerate the degenerative process and ultimately cause pathologic conditions.¹

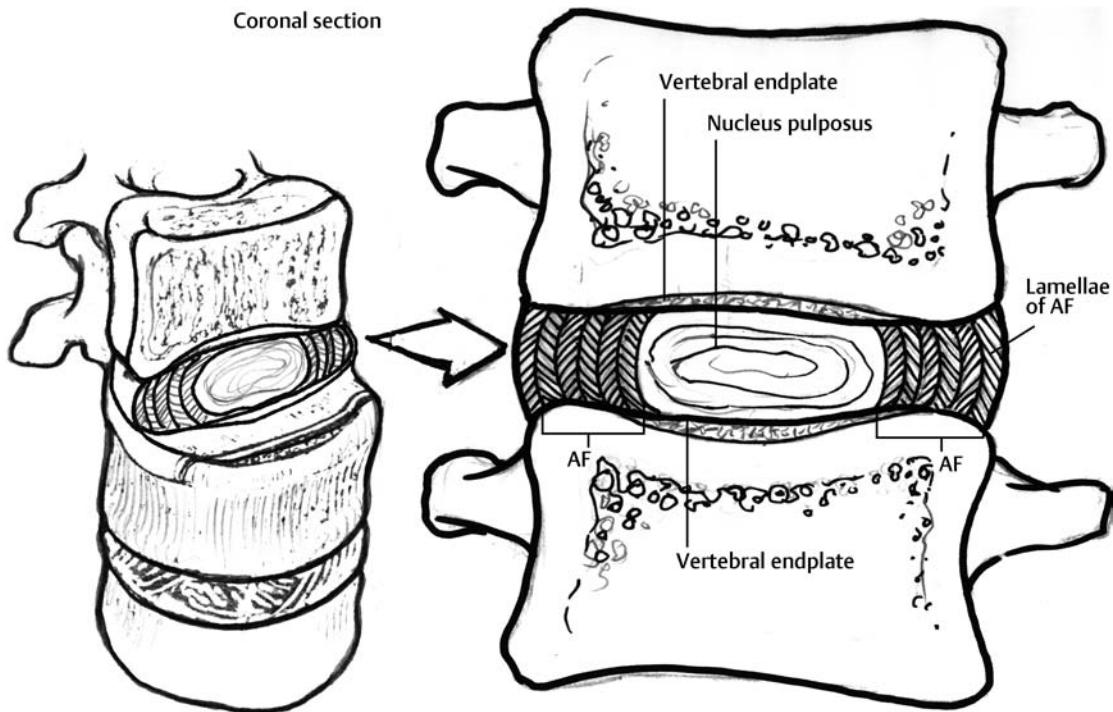


Fig. 13.1 Intervertebral disc cross-sectional anatomy. Note the oblique orientation of adjacent layers within the annulus. AF, annulus fibrosus.

With degeneration, the inner annulus fibrosus (AF) and the outer AF lose their nascent organization and differentiation; they take on a fibrocartilaginous character with indistinct boundaries. In particular, as degeneration occurs, the inner AF and the nucleus pulposus (NP) become virtually indistinguishable. As this occurs, the weakened lamellar structure of the outer AF becomes less resilient to applied forces and may develop defects that can predispose the disc both to herniations of inner disc material and to disc bulging.¹

The NP in the younger IVD is composed of a high concentration of proteoglycan that helps maintain adequate water content and preserve viscoelastic properties. As aging occurs, maintenance of disc hydration becomes compromised secondary to the tenuous blood supply and decreasing nutritional diffusion. Furthermore, there typically is a decrease in overall proteoglycan content, which leads to an inability to maintain hydration. The IVD's water content may decrease by ~20%. These changes ultimately alter disc structure, volume, and height. This change is associated with an alteration in spinal biomechanics.² Immunohistochemical studies have demonstrated deeper penetration of the inner and outer AF by nerve endings in the diseased disc. Additionally, these nerve fibers have tested positive for substance P.³

Desiccation of the NP is seen with normal physiologic aging of the lumbar spine. This loss of water content and NP volume causes the “dark disc” phenomenon commonly seen on T2-weighted magnetic resonance imaging (MRI) sequences (**Fig. 13.2**). It is often associated with buckling of the AF. Subsequently, the balance between the breakdown and anabolic repair of trivalent pyridinoline cross-links, responsible for tissue cohesiveness, may be lost. This leads to apoptosis and degeneration of arterioles supplying both the disc and the vertebral endplates. Resultant loss of nutrient and oxygen supply causes excessive lactic acid production, more apoptosis, and additional degenerative changes.⁴

■ Clinical Presentation

The most common clinical symptom thought to be directly associated with lumbar DDD is LBP. Neurologic symptoms such as radicular pain and neurogenic claudication may occur secondary to neural compression. Degeneration of intervertebral structures can be related to the development of neurological symptoms when loss of disc height, bulging of AF and ligamentum flavum, hypertrophy of facet joints, and other degenerative changes limit the space available for neural structures.

Low Back Pain and Degenerative Disc Disease

LBP is the second most common reason that patients seek medical attention and is the fifth most common reason for

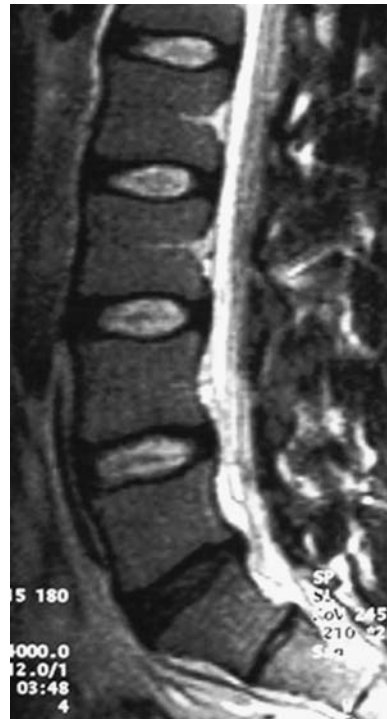

Fig. 13.2 Sagittal T2-weighted magnetic resonance image of the lumbar spine demonstrating an L5–S1 “black disc.”

all orthopaedic physician visits. It is common in industrialized countries, with prevalence estimates between 60 and 80%. The etiology of LBP is often related and or exacerbated by socioeconomic, psychological, biochemical, biomechanical, and other factors. LBP is a primary cause of physical disability and has an important socioeconomic impact.

LBP may be caused by injury as well as the degenerative processes and may be affected by poor muscle conditioning or obesity. It may also be a presenting symptom of more serious conditions, such as tumor or infection. As such, evaluating physicians should consider “red flag” signs and symptoms that may motivate a more aggressive evaluation of patients with LBP (**Table 13.1**).

Patients with LBP related to DDD typically present with nonspecific symptoms and without radiculopathy. Pain associated with DDD may arise from the paraspinal musculature, ligaments and tendons, facet joints, discs, and vertebrae. A distinct etiology is rarely identified, however. Degenerative anatomic changes in the spine that have been associated with painful disc degeneration include annular tears, herniated NP, and degenerative instability, including spondylolisthesis, lateral listhesis, and scoliosis. Patients with social and psychological stressors, depression, substance abuse, pending or past litigation or disability compensation, low socioeconomic status, work dissatisfaction, and a history of previous back pain are more likely to have persistent LBP.

Table 13.1 Medical Conditions Associated with Acute Low Back Pain

Category	Symptoms/Risk Factors	Physical Findings
Cancer	History of cancer Unexplained weight loss >10 kg within 6 months Age >50 years or <17 years Failure to improve with therapy Pain persists >4–6 weeks Night pain or pain at rest	Tenderness over the spinous process Range of motion is decreased due to protective muscle spasm
Infection	Persistent fever (>100.4°F) History of intravenous drug abuse Recent bacterial infection, urinary tract infection, or pyelonephritis Cellulitis Pneumonia immunocompromised states Systemic corticosteroids organ transplant Diabetes mellitus Human immunodeficiency virus Rest pain	Tenderness over spinous processes Decreased range of motion Vitals signs consistent with systemic infection Tachycardia, tachypnea, hypotension Elevated temperature Pelvic or abdominal mass or tenderness
Vertebral fracture	Corticosteroids Mild trauma in patients >50 years Osteoporosis in patients >70 years Recent significant trauma at any age Ejection from motor vehicle Fall from substantial height	Findings related to the site of fracture
Herniated nucleus pulposus	Muscle weakness (strength 3 of 5 or less) Foot drop	Significant progression of weakness Significant increased sensory loss New motor weakness Radicular signs
Acute abdominal aneurysm	Abdominal mass Atherosclerotic vascular disease Pain at rest or nocturnal pain Age >60 years	Pulsatile midline abdominal mass
Renal colic	Excruciating pain at costovertebral angle radiating to testis History of urolithiasis	Possible tenderness at costovertebral angle
Pelvic Inflammatory disease	Vaginal discharge Pelvic pain Prior episodes of pelvic inflammatory disease	Uterine tenderness Pelvic mass Cervical discharge
Urinary tract infection	Dysuria History of urinary tract infections	Suprapubic tenderness
Retrocecal appendix	Subacute onset without inciting event Constipation	Low-grade fever

Source: From Bratton RL. Assessment and management of acute low back pain. *Am Fam Physician* 1999;60:2299–2308.

It is typically difficult to categorize patients with DDD as to the specific cause of their LBP. Diagnostic imaging findings consistent with lumbar disc degeneration are common and can be found in 34% of people between 20 and 39 years old, 59% of people between 40 and 59 years old, and 93% of people between 60 and 80 years old.⁵ Disc degeneration, however, is not ubiquitously associated with LBP. Additionally, LBP is not always associated with

findings of degeneration on imaging studies. Indeed, it has been reported that 30% of asymptomatic subjects will have a major abnormality on an MRI of the lumbar spine.⁵ Regardless of these confounding observations, it is likely that a combination of disc degeneration and the biochemical mediators released during the degenerative process are a component of the nerve sensitization mechanism related to LBP.

Although aging and disc degeneration are commonly thought to be associated with LBP, intradiscal nerve sensitization and proliferation are thought to be important in the development of chronic LBP. A recent nerve sensitization investigation compared 19 discs excised from patients with discogenic LBP to 12 nonpainful but degenerated discs. Ten nondegenerated discs were also studied as a control. Histologic immunostaining showed that the painful discs contained increased numbers of nerve fibers sensitive to neurofilament 200, substance P, and vasoactive intestinal peptide.⁶ These inflammatory mediators are established chemical messengers for pain. Nerve sensitization is likely to be one factor to explain why similarly degenerated discs may be associated with dramatically dissimilar clinical presentations of LBP.

Excessive nerve growth with subsequent nerve sensitization may be caused by disc degeneration and may be a central origin of LBP for many patients.⁶ Nerve ingrowth occurs primarily within vascularized granulation tissue, extending from the NP to the outer AF, along tears likely resulting from disc degeneration. During compression and movement, fluid may leak from these fissures causing irritation. Release of inflammatory cytokines such as prostaglandin E2 and interleukins 6 and 8 may be responsible for nerve sensitization in the painful disc. Nitric oxide and phospholipase A2 have also been detected in the granulation tissue.⁶ Using similar pathways, these mediators have been linked to hyperalgesia in animal studies.⁷

Matrix metalloproteinases (MMPs) have also been implicated in LBP. They are a family of zinc-utilizing enzymes that are suspected to be active in disc herniation and posterior longitudinal ligament rupture. Inflammatory mediators upregulate MMP action and are therefore found densely within the granulation tissue. It is speculated that the wide array of MMP actions such as neovascularization and macrophage infiltration may be responsible for spontaneous disc resorption after herniation.⁴

Discogenic Back Pain

The overall rate of resolution of discogenic back pain remains unpredictable. It is thought that ~90% of people with acute onset LBP, which may or may not be discogenic, will experience complete relief within 2 to 6 weeks. For those who do not experience relief, symptoms will consist of persistent axial low back and buttock pain. The pain is often described in vague terms as deep LBP that is made worse by bending, sitting, and axial loading. Symptoms are often alleviated with rest and positions that allow for lumbar extension thereby unloading the involved disc.

Plain radiographs may demonstrate nonspecific changes, without apparent instability, including facet degenerative changes and vertebral endplate sclerosis. MRI

studies may demonstrate loss of disc height; disc bulging and concomitant spinal stenosis may develop. If surgery is being considered, provocative discography to confirm a diagnosis of discogenic back pain is often performed.

The mainstays of treatment continue to be based on the use of antiinflammatory, analgesic, and muscle relaxant medications. Flexible and/or rigid bracing may also be employed, taking advantage of reduced intradiscal pressure in lumbar extension. A physical therapy program may be recommended that emphasizes stretching, strengthening, extension-based exercises, as well as nonimpact exercises.⁸

Radiculopathy and Degenerative Disc Disease

Nerve root irritation may cause radiculopathy and can be associated with pain radiating to one or both lower extremities. The typical natural history of radicular pain related to disc herniation is one of resolution in ~90% of cases over 6 to 8 weeks. Radicular pain due to a herniated NP may be severe and often overwhelms any underlying back pain due to the painful disc degeneration. The symptoms of radiculopathy may be relieved by assuming a supine position and accentuated by standing or sitting. Many patients report that the most comfortable position is supine with hips and knees flexed at 90 degrees.

Neurogenic Claudication and Degenerative Disc Disease

Central disc bulging or herniation can produce spinal stenosis and present as neurogenic claudication in the lumbar spine. Most often, it is the older patient that is affected, who displays a constellation of symptoms including LBP and characteristic leg pain with ambulation. Positions that flex the spine are able to slightly increase canal diameter and therefore reduce neural compression resulting in an alleviation of symptoms. It is believed that acute deterioration of symptoms is rare, but that neurogenic claudication may coexist with lumbar radiculopathy in the event of concomitant foraminal stenosis.⁹

Conclusion

The clinical presentation of lumbar DDD may be variable, but certain characteristics may be shared among patients. LBP is a nearly ubiquitous symptom, which may or may not be associated with abnormal physical or imaging findings. Comprehension of the typical presentations and natural histories of DDD may help the clinician to identify more significant pathologies and red flag situations.

References

1. Roh JS, Teng AL, Yoo JU, et al. Degenerative disorders of the lumbar and cervical spine. *Orthop Clin North Am* 2005;36:255–262
2. Dickerman RD, Zigler JE. Discogenic back pain. In: Spivak JM, Connolly PJ, eds. *Orthopaedic Knowledge Update Spine 3*. Rosemont, IL: American Academy of Orthopaedic Surgeons; 2006:319–329
3. Coppes MH, Marani E, Thomeer RT, et al. Innervation of “painful” lumbar discs. *Spine* 1997;22:2342–2349
4. Biyani A, Andersson GBJ. Low back pain: pathophysiology and management. *J Am Acad Orthop Surg* 2004;12:106–115
5. Boden SD, Davis DO, Dina ST, et al. Abnormal magnetic-resonance scans of the lumbar spine in asymptomatic subjects. *J Bone Joint Surg Am* 1990;72:403–408
6. Peng B, Wu W, Hou S, et al. The pathogenesis of discogenic low back pain. *J Bone Joint Surg Br* 2005;87B:62–67
7. Ahmed M, Bjurholm A, Kreicbergs A, et al. Neuropeptide Y, tyrosine hydroxylase and vasoactive intestinal polypeptide-immunoreactive nerve fibers in the vertebral bodies, discs, dura mater, and spinal ligaments of the rat lumbar spine. *Spine* 1993;18:268–273
8. Rao RD, David KS. Lumbar degenerative disorders. In: Vaccaro AR, ed. *Orthopaedic Knowledge Update 8*. Rosemont, IL: American Academy of Orthopaedic Surgeons; 2005:539–549
9. Furey CG. Differential diagnosis of spinal disorders. In: Spivak JM, Connolly PJ, eds. *Orthopaedic Knowledge Update Spine 3*. Rosemont, IL: American Academy of Orthopaedic Surgeons; 2006:83–89